

Candidate name: \_\_\_\_\_

Department of  
Emergency Medicine

Princess Alexandra Hospital

**FELLOWSHIP TRIAL EXAMINATION  
2018.2**

**WRITTEN EXAMINATION**

**SHORT ANSWER QUESTIONS**

**PROPS  
BOOKLET**

Candidate initials: \_\_\_\_\_

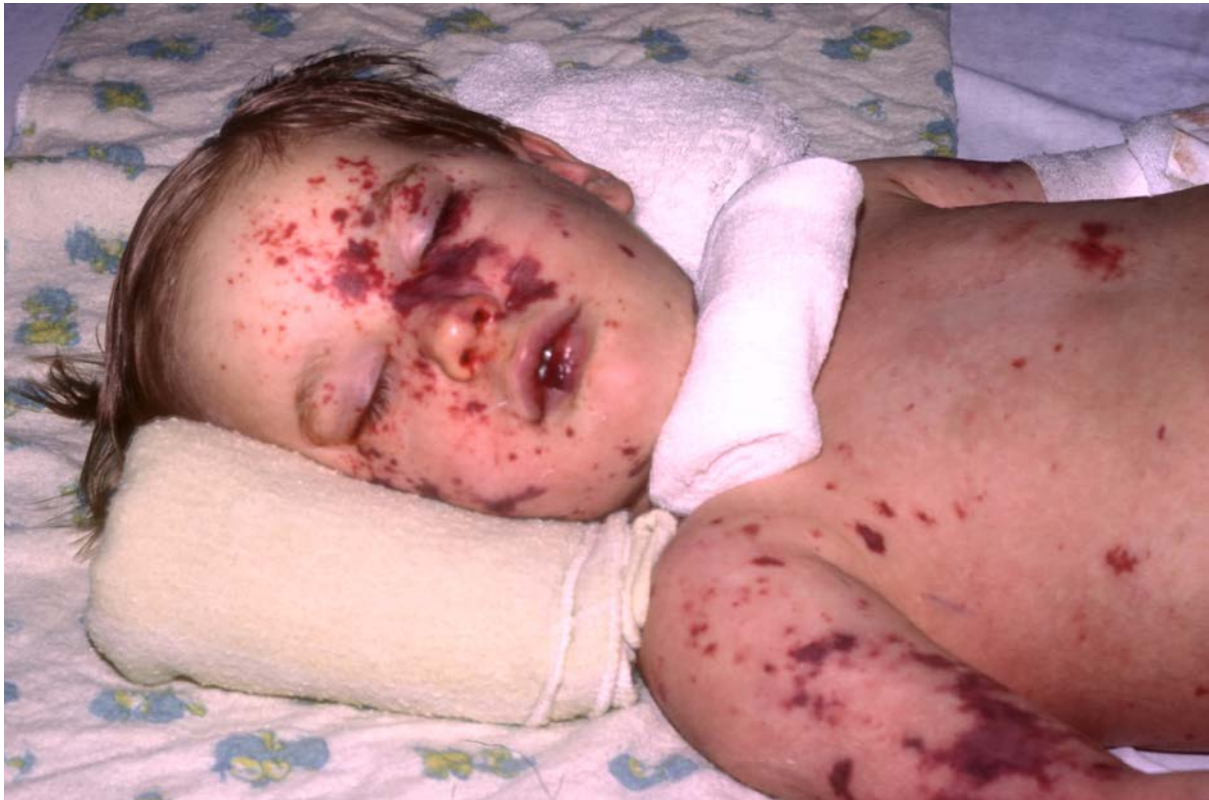Candidate initials: \_\_\_\_\_

**Q1 (12 min)**

A 3 year old boy has been brought to the ED by ambulance. He has been unwell with fever and vomiting for 2 days. He has developed lethargy and a rash this morning.

The child is unvaccinated.

A clinical photograph has been provided **BELOW**.



Candidate initials: \_\_\_\_\_

**Q1 (cont)**

The patient stabilises after your initial management.

One of your laboratory tests is provided **BELOW**.

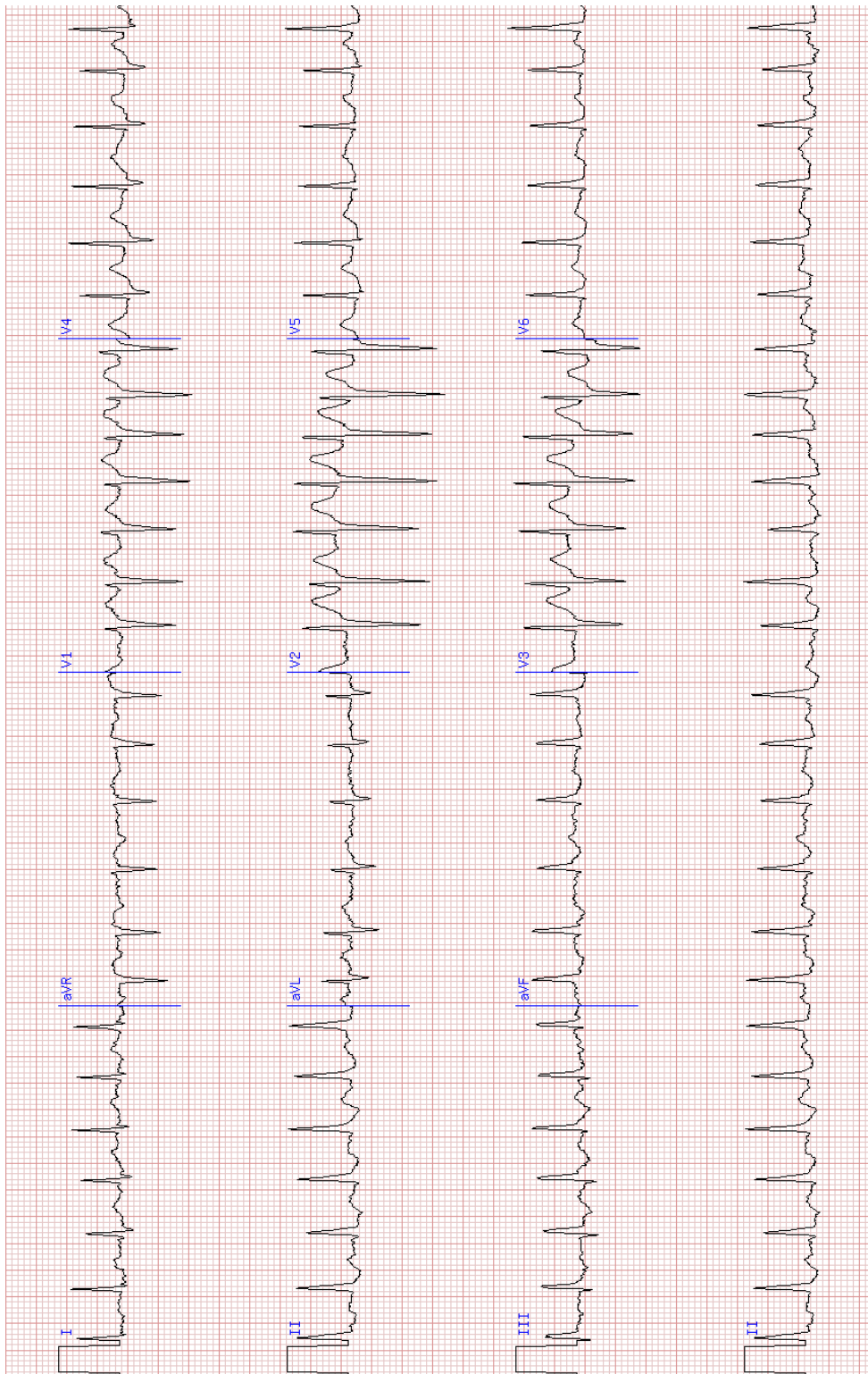
Coagulation profile

INR	3.2		(0.9 – 1.7)
aPTT	83	s	(24 – 39)
Fibrinogen	1.7	g/L	(1.7 – 4.5)
D-dimer	35	mg/L	(<0.5)
Platelet count	59	*10 <sup>9</sup> /L	(150 – 400)

**Q3**

A 77 year old lady has presented with palpitations.

Her ECG is provided **BELOW**.



Candidate initials: \_\_\_\_\_

**Q7**

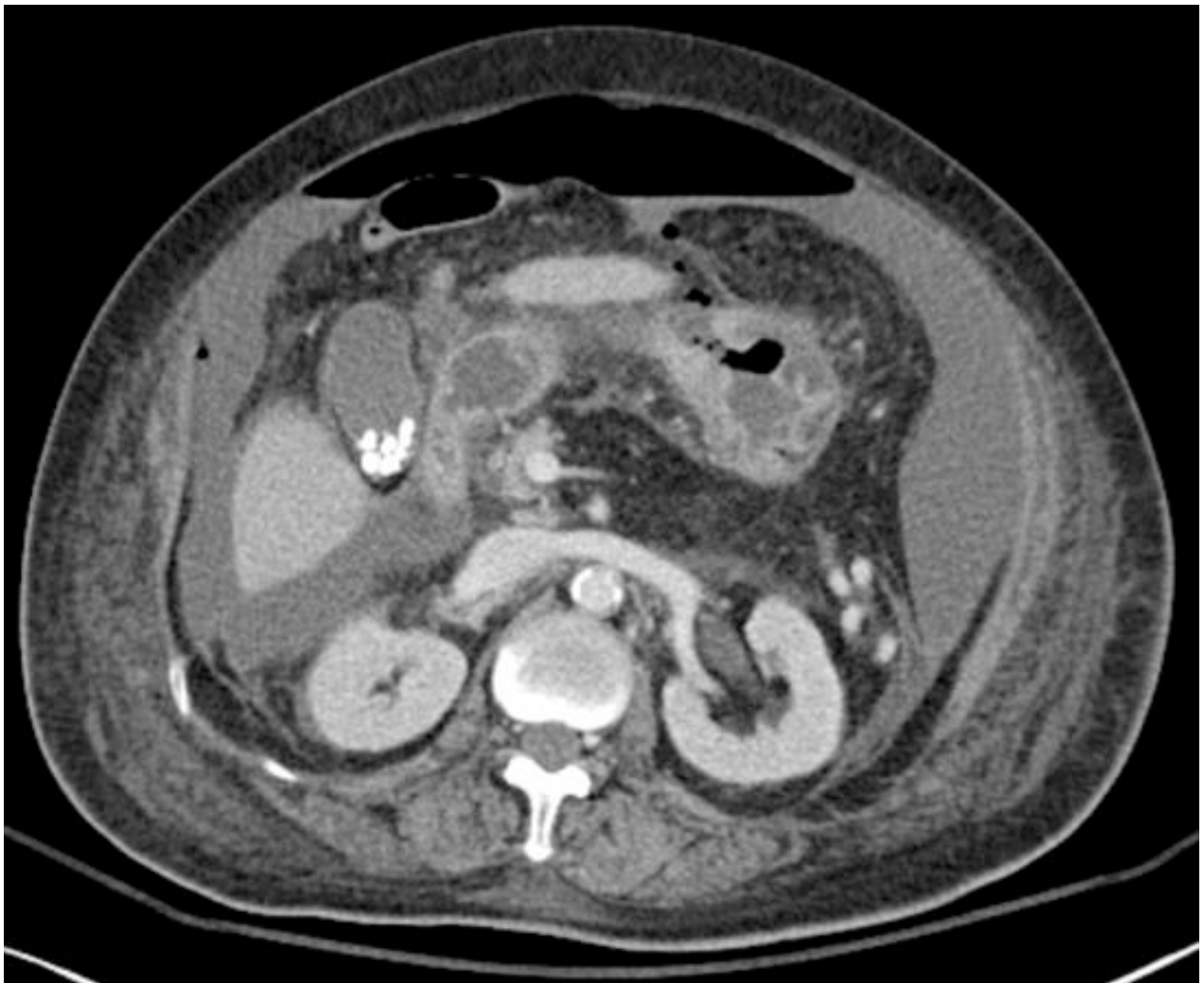A 65 year old woman has presented to the ED with severe generalised abdominal pain.

Examination reveals a generally tender and guarded abdomen.

Her vital signs are:

GCS	15	
Pulse	120	/min
BP	95/55	mmHg
O2 sats	96%	room air

A slice from her abdominal CT scan is provided **BELOW**.



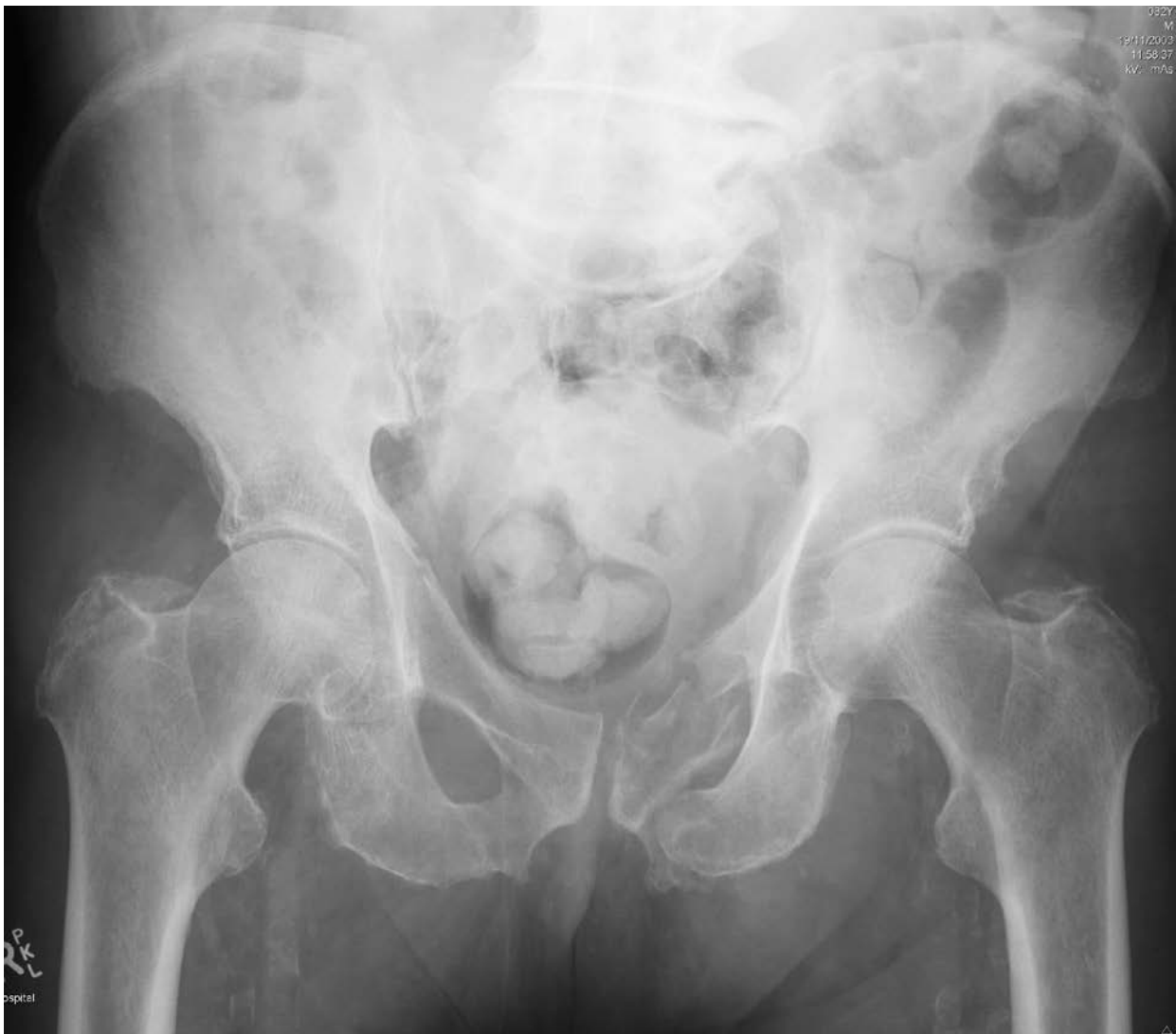Candidate initials: \_\_\_\_\_

**Q9**

A 79 year old man has been brought to the ED after falling in the car park of his local shopping centre.

He has pain in his pelvis.

An x-ray of his pelvis is provided **BELOW**.



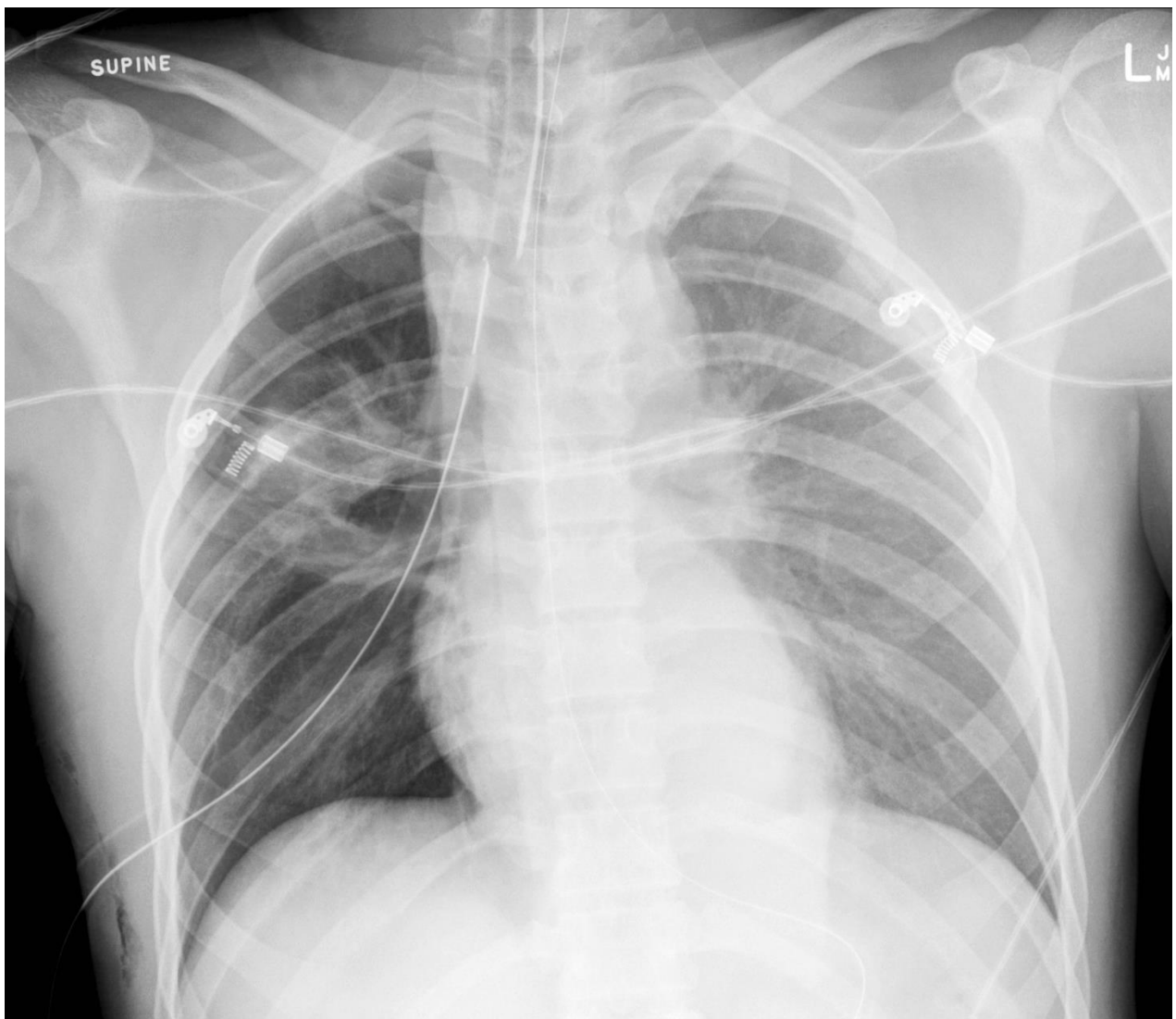
Candidate initials: \_\_\_\_\_

**Q10 (12 min)**

A 25 year old man has been brought to your tertiary ED after a major motor vehicle accident. He was the driver of a van that collided head-on with an on-coming sedan on a stretch of highway.

The patient was retrieved by helicopter from a rural hospital where he was intubated due to a reduced level of consciousness and had a right sided intercostal catheter inserted.

His initial chest x-ray is provided **BELOW**.





**Q10 (cont)**

As part of your initial management, an arterial blood gas has been taken.

The result is provided **BELOW**.

Arterial blood gas

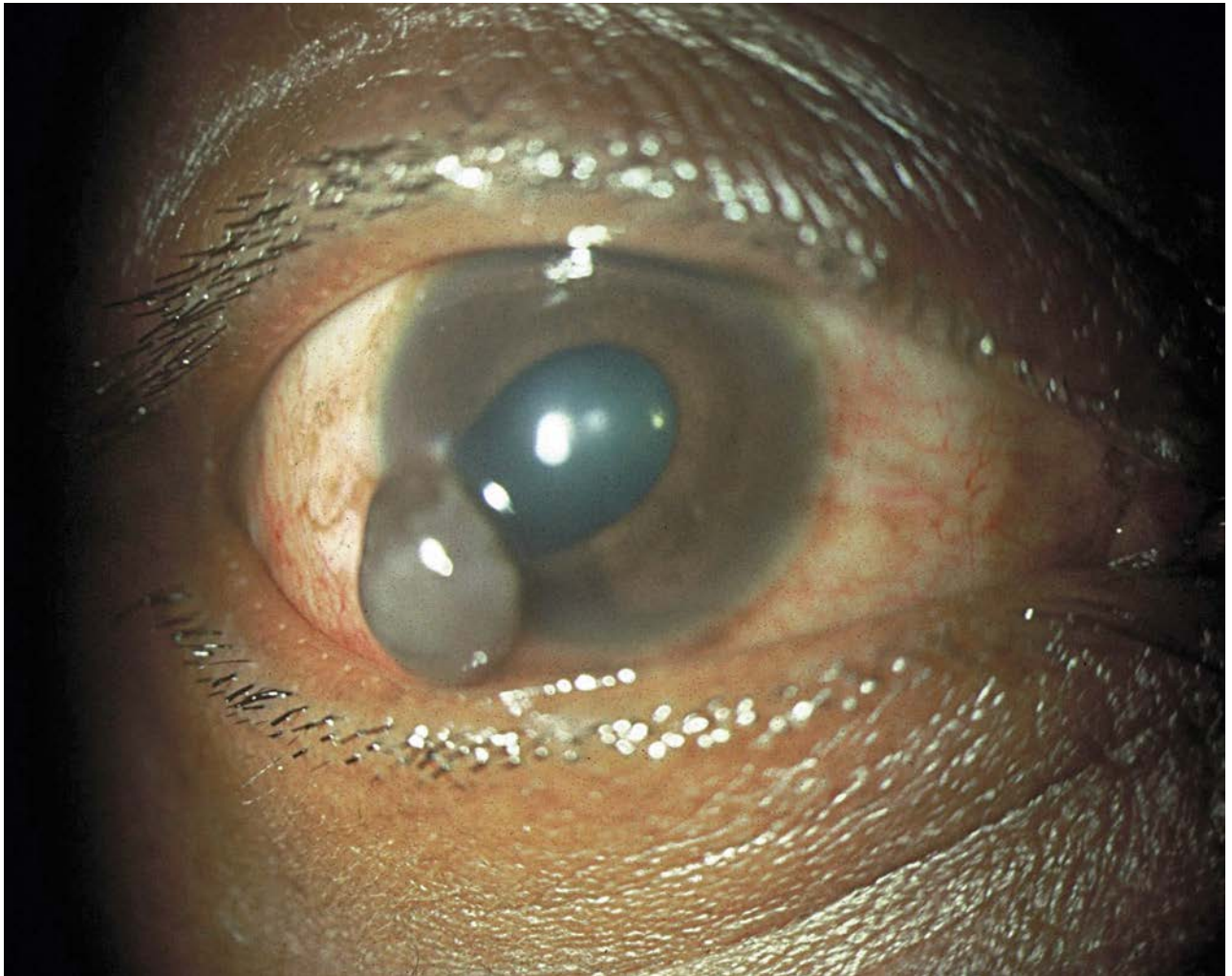
FiO <sub>2</sub>	0.4		
pH	6.86		(7.35 – 7.45)
pCO <sub>2</sub>	75	mmHg	(35 – 45)
pO <sub>2</sub>	55	mmHg	
HCO <sub>3</sub>	13	mmol/L	(22 – 33)
Na	138	mmol/L	(135 – 145)
K	6.1	mmol/L	(3.5 – 5.2)
Cl	101	mmol/L	(95 – 110)
Lactate	11.5	mmol/L	(0.5 – 2.2)

Candidate initials: \_\_\_\_\_

**Q13**

A 45 year old man has presented to the ED with right eye pain after an injury at work where he was hammering metal.

A clinical photograph of his right eye is provided **BELOW**.

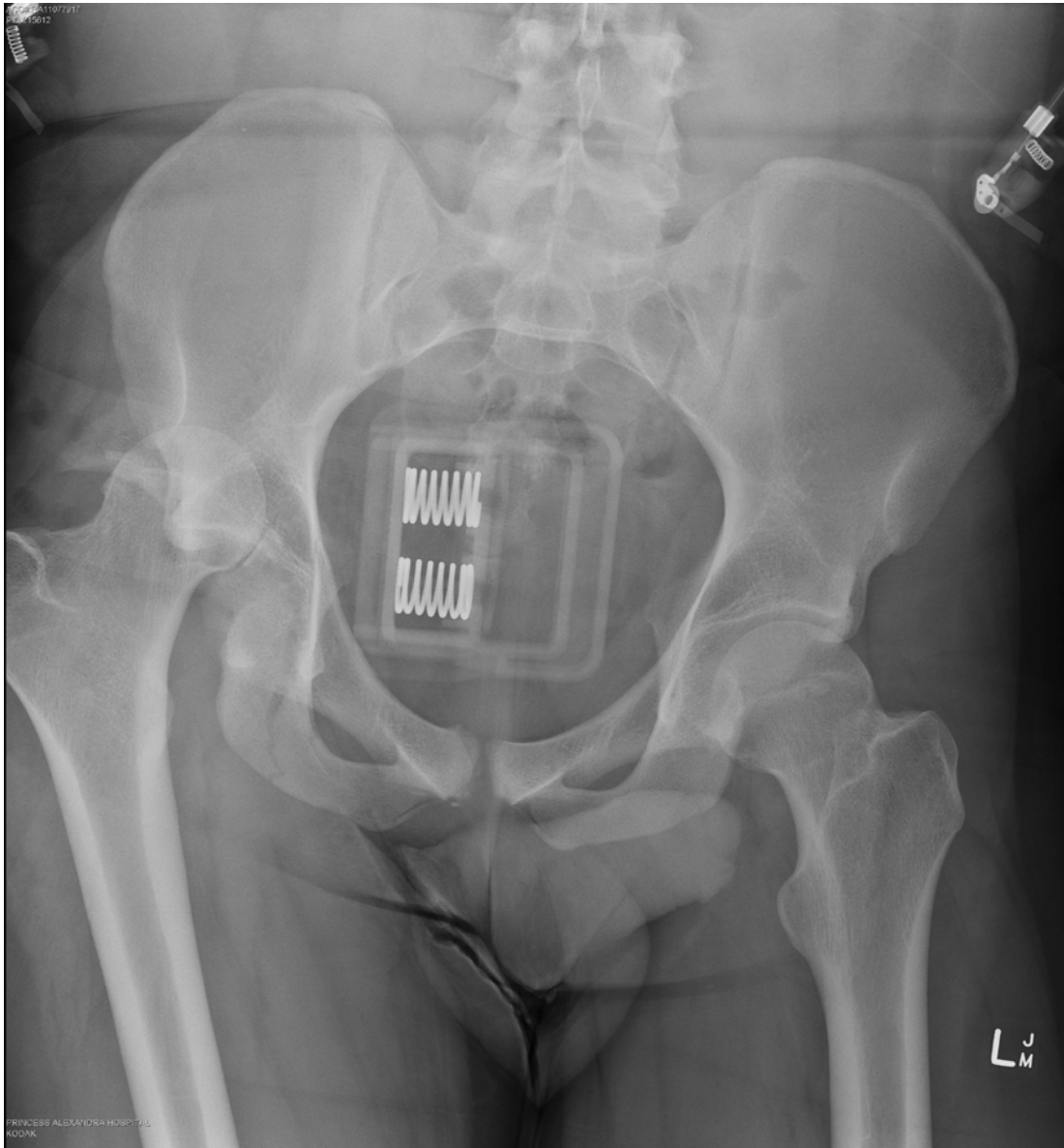


Candidate initials: \_\_\_\_\_

**Q16**

A 47 year old father was enjoying his daughter's birthday at a trampoline park when he fell awkwardly on to his right knee. He is complaining of right hip pain.

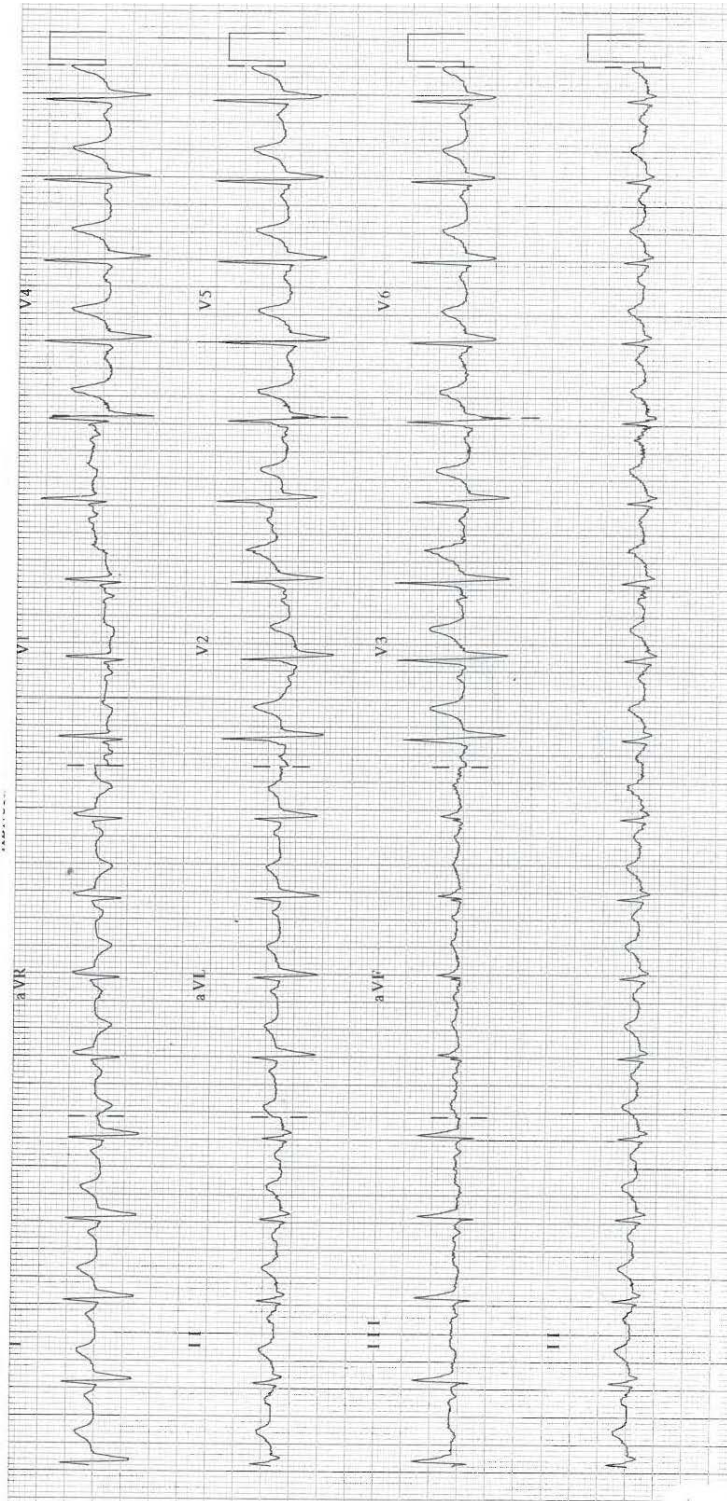
His pelvic x-ray is provided **BELOW**.



**Q17**

A 67 year old woman has presented to the ED after a cardiac arrest at home. She was seated on the couch watching television when she suddenly complained of chest pain, became blue and stopped breathing. Upon arrival of the ambulance service, she was unresponsive with pulseless electrical activity. Standard advanced life support resulted in a return of spontaneous circulation.

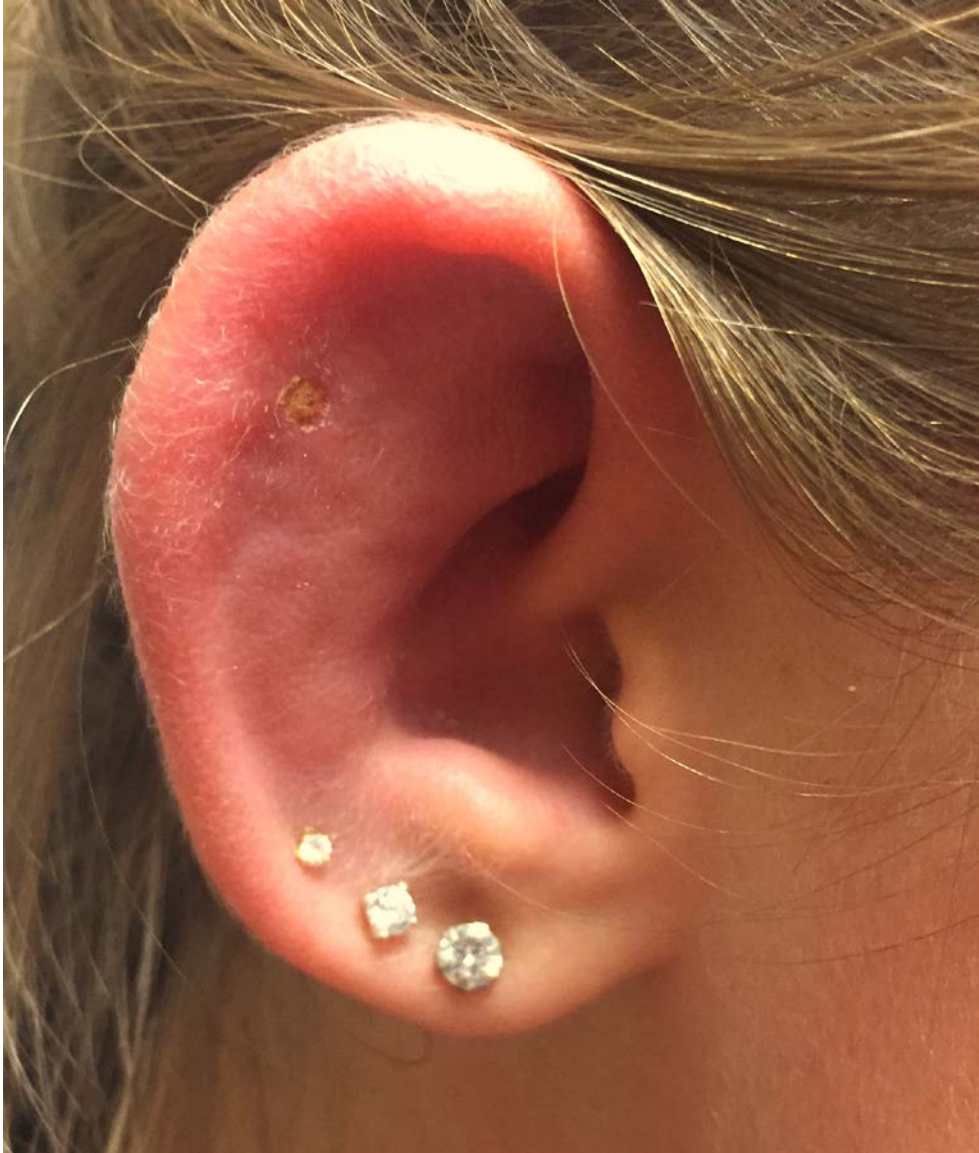On arrival to the ED, an ECG has been performed. It is provided **BELOW**.



**Q22**

A 16 year old girl has presented with right ear pain.

A clinical photograph is provided **BELOW**.

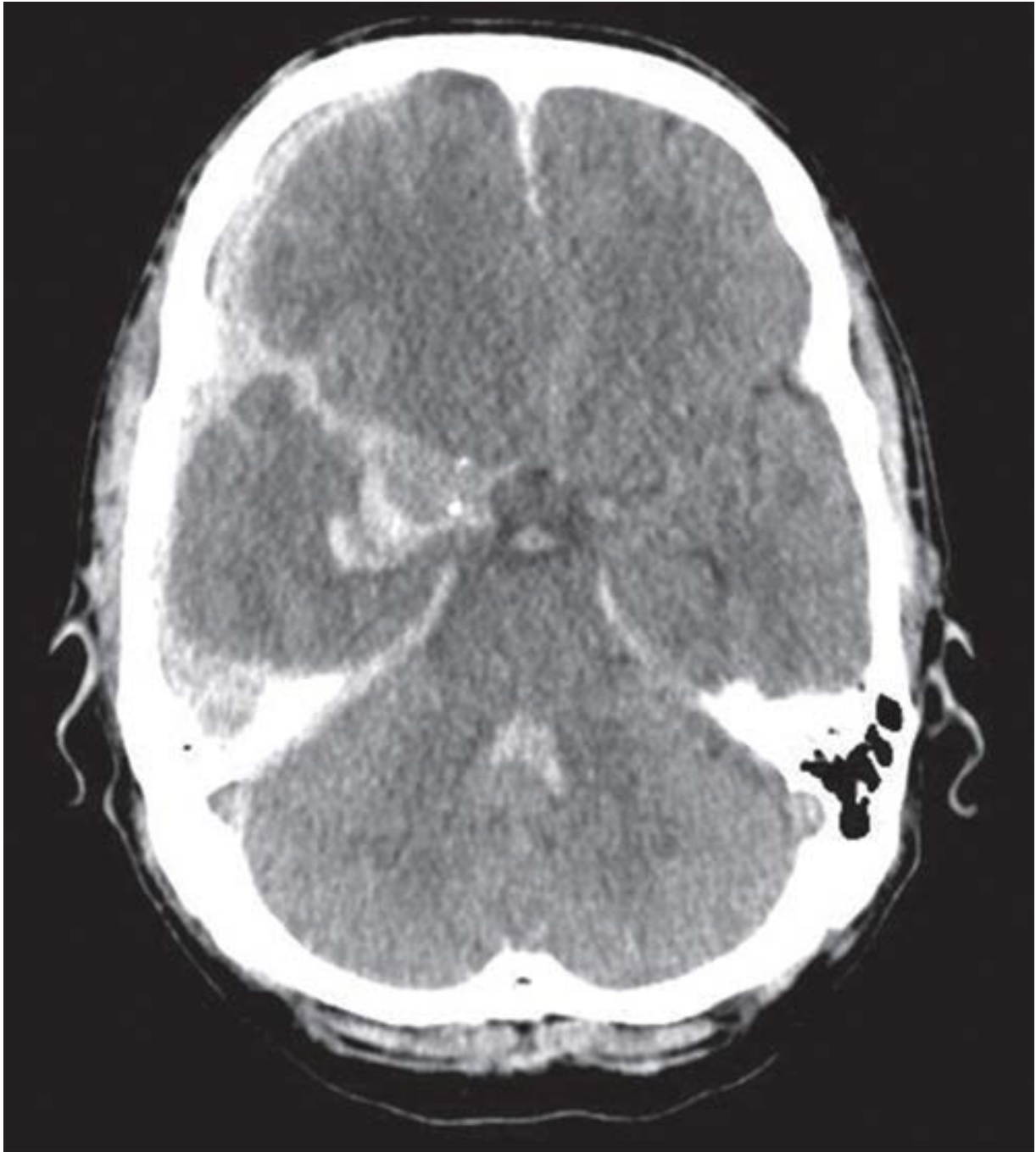


Candidate initials: \_\_\_\_\_

**Q24 (9 min)**

A 50 year old woman has been brought to the ED following a collapse at work. She had complained of a severe headache prior to her collapse.

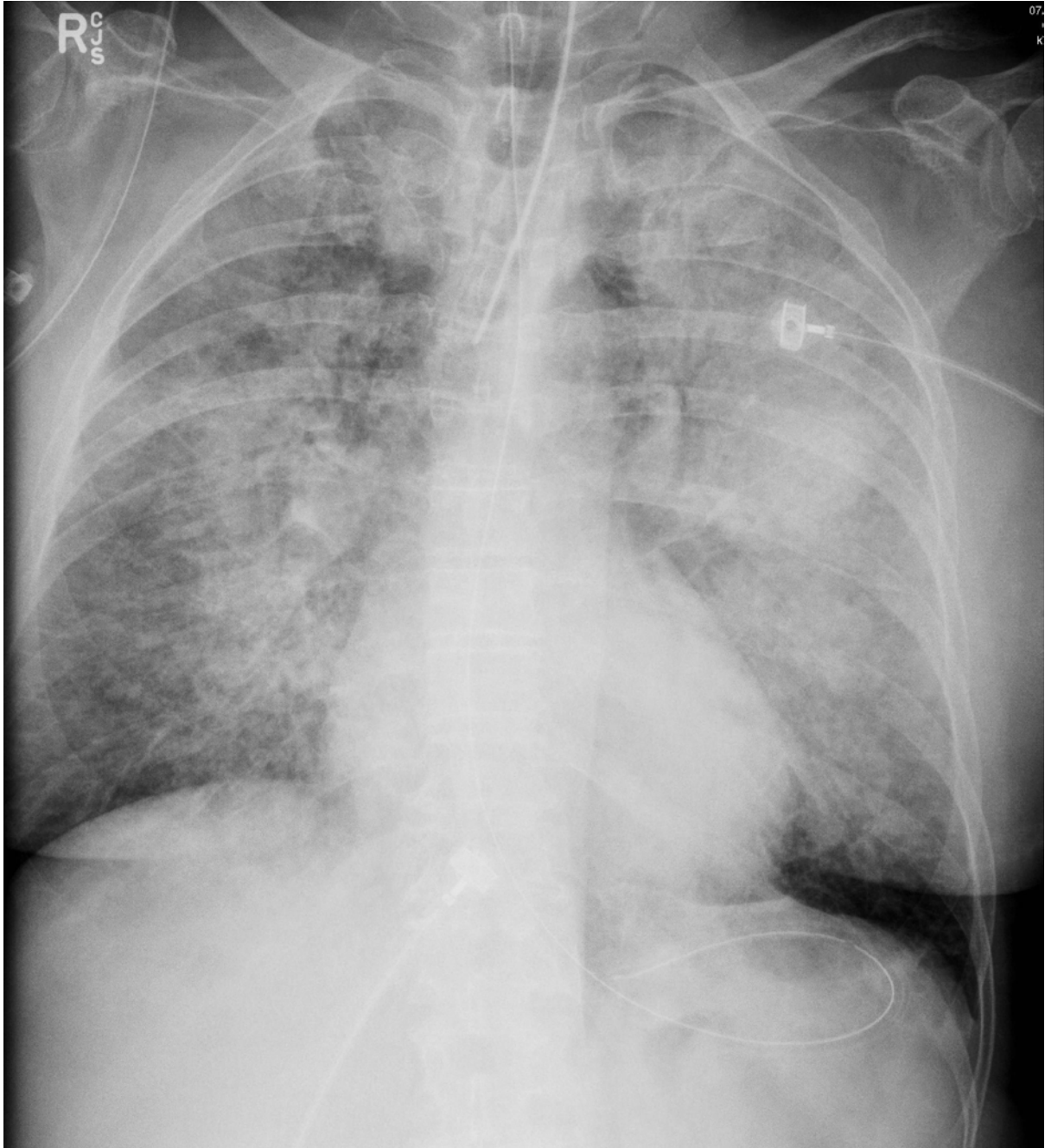
A slice from the CT scan of her head is provided **BELOW**.



Candidate initials: \_\_\_\_\_

Q24 (cont)

A chest x-ray has been performed. It is provided **BELOW**.



**Q26**

A 28 year old woman has been taken to the ED after being found unconscious on the floor of her apartment. She was last seen 24 hours prior.

Some of her blood results are provided **BELOW**.

Blood chemistry

Na	136	mmo/L	(135 – 145)
K	8.4	mmol/L	(3.5 – 5.1)
Cl	100	mmol/L	(100 – 110)
HCO <sub>3</sub>	18	mmol/L	(22 – 32)
Glucose	7.3	mmol/L	(3.0 – 7.8)
Urea	18.0	mmol/L	(2.9 – 8.2)
Creatinine	156	umol/L	(64 – 108)
CK	116000	U/L	(46 – 171)